

OCCIPITAL CONDYLE FRACTURES

RECOMMENDATIONS

Diagnostic:

Standards: There is insufficient evidence to support diagnostic standards.

Guidelines: CT imaging is recommended for establishing the diagnosis of occipital condyle fractures. Clinical suspicion should be raised by the presence of one or more of the following criteria: blunt trauma patients sustaining high energy craniocervical injuries, altered consciousness, occipital pain or tenderness, impaired cervical motion, lower cranial nerve paresis, or retropharyngeal soft tissue swelling.

Options: MR imaging is recommended to assess the integrity of the craniocervical ligaments.

Treatment:

Standards: There is insufficient evidence to support treatment standards.

Guidelines: There is insufficient evidence to support treatment guidelines.

Options: Treatment with external cervical immobilization is recommended.

RATIONALE

Although traumatic occipital condyle fracture (OCF) was first described by Bell in 1817, more frequent observation of this injury has only been reported during the past two decades.(2) Improvements in computed tomographic (CT) imaging technology and use of CT imaging of the head-injured patient that includes the craniovertebral junction have resulted in more frequent

recognition of this injury. However, the overall infrequent occurrence of OCF and missed diagnoses in patients with OCF may result in late neurological deficits in these patients. An analysis of the reported cases of OCF may facilitate development of diagnostic and treatment recommendations for this disorder and are undertaken in this report. Specific questions that were evaluated include: accuracy of plain radiographs and CT imaging in the diagnosis of OCF, as well as the safety and efficacy of various treatment modalities including no treatment, traction, external immobilization, decompression and internal fixation with fusion.

SEARCH CRITERIA

A National Library of Medicine computerized literature search of publications from 1966 to 2001 was performed using the following headings: occipital bone and fracture (spinal, skull, or fracture alone). An exploded search of the headings led to 1,830 and 33,537 citations, respectively. A subset of 218 citations contained both headings. The references of the identified articles were also reviewed to identify additional case reports. The articles were reviewed using the following criteria for inclusion in diagnosis: human survivors, type of fracture, tomographic or plain radiographic findings. The articles were also reviewed using the following criteria for inclusion in treatment: human survivors, type of fracture, management, and outcome. Since fewer than 100 cases of survivors were identified, even single case reports were considered, provided that basic inclusion criteria were met. The observations from the reports were combined because the usual methods for analysis were precluded by the infrequent occurrence of this injury. Forty-seven articles met the selection criteria, providing data on a sum total of 91 patients for this review. All but two articles contained Class III data of either single case studies

or small case series with none containing more than fifteen patients. The two exceptions were prospective studies to evaluate the use of clinical criteria in blunt trauma patients to prompt CT imaging of the skull base (4,26). The duration of follow-up in all articles ranged from several weeks to five years. The data provided by these reports was compiled and make up the basis for this guideline. Summaries are provided in Evidentiary Table format.

SCIENTIFIC FOUNDATION

Diagnosis:

Plain radiographs of the cervical spine were obtained in nearly all 91 patients culled from the literature review. Normal imaging was reported in 42 patients. Eight patients had prevertebral soft tissue swelling (STS), only four of whom did not have associated cervical fractures.(17,28,30,41) Ten patients with cervical fractures or displacements were described without mention of the presence or absence of STS. Three patients had multiple cervical fractures. Associated fractures included atlas-four, Type II odontoid-two, axis-three, C5 fractures-two, C3, C6, and C7 fractures- one each, and unspecified cervical fractures-one. One patient had atlantoaxial widening and one had C5-C6 subluxation. Only two patients were identified with OCF on plain radiographs of the skull or cervical spine.(21,44) The results of plain radiographs were not reported in 28 patients and plain radiographs were not performed in one patient with an old healed fracture identified with CT imaging.(12) The calculated sensitivity of plain radiographs from these reports in the diagnosis of OCF is 3.2% (two of 62). Since the data were obtained from case reports and small case series of patients known to have OCF, comparison with the findings of plain radiographs in patients without OCF could not be

performed. As a result, specificity, positive predictive value, and negative predictive value could not be determined.

The type of fracture was classified according to Anderson and Montesano (1) into Type I (comminuted from impact), Type II (extension of a linear basilar skull fracture), and Type III (avulsion of a fragment) fractures (Figure 1). The 91 patients in this review population provided data on 12 Type I, 24 Type II, 49 Type III unilateral fractures, four bilateral fractures (one Type I, two Type III, and one mixed Type I and Type III), and two old fractures.

All but one patient underwent tomographic imaging (polytomography alone-six, CT imaging alone-83, and both-one). One OCF was missed with polytomography and subsequently identified on CT.(33) Two patients had OCF diagnosed from retrospective review of CT images that were initially interpreted as normal. The diagnosis of OCF could be made in every patient with OCF. Bloom et al performed a prospective study over one year to identify the frequency of OCF in patients meeting certain clinical criteria.(4) Fifty-five consecutive patients with high energy blunt craniocervical trauma underwent thin-section craniocervical junction CT imaging. Supplemental criteria included reduced Glasgow Coma Score (GCS) on admission, occipitocervical tenderness, reduced craniocervical motion, lower cranial nerve abnormality, and retropharyngeal soft tissue swelling (STS). Nine of 55 patients (16.4%) were identified with OCF. Other reports have estimated a 1% to 3% frequency of OCF in patients sustaining blunt craniocervical trauma.(24,31) Similarly, Link et al reported the results of craniocervical CT on 202 patients with a Glasgow Coma Score between three and six.(26) OCF was identified in nine of 202 (4.4%).

Loss of consciousness was observed in 36 of 44 patients. Among 64 patients who had a sufficiently detailed neurological examination reported, 25 were normal, 24 had acute or delayed cranial nerve deficits alone, six had cranial nerve deficits with limb weakness, six had mild to severe limb weakness without cranial nerve deficits, one had a delayed onset of vertigo, one had hyperreflexia, and one had diplopia. Only four patients were found who did not have occipitocervical pain in the absence of significantly impaired consciousness.(28,32,41) One patient was intoxicated, one had severe extremity pain, and the other two had severe facial trauma.

Only 11 patients were investigated with MRI. Early craniocervical MR imaging was performed in eight patients, whereas late MR studies were obtained in three patients. Cervicomedullary hemorrhages were seen in three patients, two had normal imaging, one had a retrodental hemorrhage, one had a torn tectorial membrane, and one had demonstration of the fracture. Displaced fracture fragments were observed in all three patients with delayed MR imaging. Although acute MR imaging has been infrequently reported after OCF, Tuli et al proposed a new classification scheme using MR imaging to differentiate stable from unstable OCF.(41) However, the case example they gave demonstrated concurrent atlantoaxial instability which prompted occipitocervical fusion (rather than atlantooccipital instability and OCF fracture).

In summary, the diagnosis of OCF is rarely made on plain radiographs. Imaging of the craniovertebral junction with CT or other tomographic methods is recommended in patients suspected of having OCF. Blunt trauma patients sustaining high energy craniocervical injuries may be more likely to sustain OCF. Consequently, cranial imaging should include evaluation of

the craniocervical junction. Other clinical criteria including altered consciousness, occipital pain or tenderness, impaired craniocervical motion, lower cranial nerve paresis, or retropharyngeal STS should prompt CT imaging of the craniocervical junction.

Treatment:

Twenty-three patients (Type I-two, Type II-fourteen, Type III-five, unknown type-two) did not receive treatment. Nine of these patients (Type I-one, Type II-four, Type III-four) developed cranial nerve deficits within days to weeks after injury.(6,9,12,13,31,33,34,42,45) One hypoglossal nerve palsy resolved, two hypoglossal nerve deficits improved, three other cranial nerve deficits persisted (two hypoglossal, one glossopharyngeal and one vagal), and three outcomes were not reported. Six additional patients developed delayed deficits or symptoms. Two initially untreated patients (Type II-one, Type III-one) developed multiple lower cranial nerve deficits which improved with six weeks of cervical immobilization.(23) Another initially untreated patient (Type III) developed vertigo after three months that resolved after eight weeks of collar immobilization.(7) One patient (Type III) developed nystagmus and a lateral rectus palsy after precautionary collar immobilization was discontinued. The deficit resolved after resuming cervical immobilization.(14) One patient (Type III) developed double vision during cervical traction which resolved with surgical decompression.(45) Finally, one patient (Type III) developed delayed vagal, spinal accessory and hypoglossal nerve palsies during cervical immobilization in a cervical collar.(8) The cranial nerve X and XI palsies improved. However, the hypoglossal palsy persisted at one year.

Forty-four patients were treated with cervical collar immobilization (Type I-eight, Type II-eight, Type III-twenty-eight). Thirteen patients were treated with halo/Minerva immobilization (Type I-two, Type III-eleven). Treatment was unreported in six patients.

Five patients (Type II-one, Type III-four) underwent surgery. Two patients with Type III OCF were treated with occipitocervical fusion (one with concurrent atlantooccipital dislocation and one with atlantoaxial instability).(21,41) One patient (Type III) with delayed diplopia had symptom resolution after removal of the fracture fragment (45), while one patient (Type II) with lower cranial nerve deficits (37) and one (Type III) with diplopia and hemiparesis (7) remained unchanged several days after surgery. The latter patient subsequently recovered normal function.

In summary, twelve of fifteen patients who developed delayed symptoms or deficits were not initially treated. Only three of these twelve patients were subsequently treated with cervical immobilization. All three improved. In comparison, only three of six patients demonstrated improvement in deficits without treatment. Only one patient (Type III) developed a deficit during treatment that persisted (hypoglossal nerve palsy) despite collar use. Only three patients underwent surgery for decompression of the brainstem, one of whom had immediate and lasting improvement in symptoms post-operatively. Because 12 of 23 patients developed delayed deficits without treatment and another developed a deficit after premature discontinuation of treatment, the literature suggests that patients with Type III OCF should be treated with external immobilization. Treatment of patients with OCF Types I and II may include external immobilization.

SUMMARY

OCF is an uncommon injury requiring CT imaging for diagnosis. Patients sustaining high energy blunt craniocervical trauma, particularly in the setting of loss of consciousness, impaired consciousness, occipitocervical pain or motion impairment, and lower cranial nerve deficits, should undergo CT imaging of the craniocervical junction. Untreated patients with OCF often develop lower cranial nerve deficits that usually recover or improve with external immobilization. Identification of Type III OCF should prompt external immobilization. Additional treatment may be dictated by the presence of associated cervical fractures or instability.

KEY ISSUES FOR FUTURE INVESTIGATION

Although Type III occipital condyle fractures are considered by many authors to be unstable, not all patients, treated or not, developed neurological deficits. CT imaging with three dimensional reconstruction for more precise measurement of the magnitude of fracture displacement and MR imaging for differentiation of partial and complete ligamentous injuries may be useful in identifying subgroups of patients who do not require treatment or conversely require more rigid halo immobilization, rather than collar immobilization. Because OCF injuries remain relatively infrequent, cooperative retrospective collection of plain radiograph, CT and MR imaging data in patients with OCF is recommended.

EVIDENTIARY TABLES

AUTHOR	AGE	SEX	TYPE	LOC	PAIN	PLAIN	CT	MR	EXAM	TX	OUTCOME
Legros B et al, 2000, <i>J Trauma</i> (23)	71	F	III	-	Unrep	Unrep	L,+	Epidural	Del6,7,10	6wk collar	18mo 10
	44	M	II	-	Unrep	Unrep	R,+	Normal	Del6,9-12	6wk collar	3.5mo 10
Ide C et al, 1998, <i>J Neurosurg</i> (19)	25	M	III	+	+	STS, C1fx	R,+	Tectear	Normal	10wkcollar	10wk Normal
Demish S et al, 1998, <i>Clin Neurol Neurosurg</i> (13)	45	F	II	Unrep	Unrep	Unrep	R,+	Fracture	Del12	None	1yr imp12
Bloom AI et al, 1997, <i>Clin Radiol</i> (4) Class II	21	M	III	Unrep	Unrep	STS,C67Fx	R,+	Unrep	Normal	>8wk collar	Normal
	36	F	III	Unrep	Unrep	Unrep	L,+	Unrep	Normal	>8wk collar	Pain
	15	F	I/I	Unrep	Unrep	Unrep	B,+	Unrep	Qparesis	>8wk collar	Imp Qparesis
	45	F	III/I	Unrep	Unrep	Unrep	B,+	Unrep	12	>8wk collar	Pain,12
	22	F	II	Unrep	Unrep	Unrep	R,+	Unrep	Normal	>8wk collar	Unrep
	21	M	I	Unrep	Unrep	STS,C125F	R,+	Unrep	Normal	>8wk collar	Unrep
	41	M	I	Unrep	Unrep	x	R,+	Unrep	Normal	>8wk collar	Normal
	6	F	II	Unrep	Unrep	Unrep	L,+	Unrep	Normal	>8wk collar	Normal
	25	F	I	Unrep	Unrep	Unrep	L,+	Unrep	Normal	>8wk collar	Unrep
20	M	I	Unrep	Unrep	STS,C2Fx CFx	R,+	Unrep	Pplegia	>8wk collar	Unrep	
Tuli S et al, 1997, <i>Neurosurgery</i> (41)	64	F	III	Unrep	+	STS	R,+	None	Normal	12wk collar	3mo Normal
	69	F	III	Unrep	-	AAWide	L,+	Fracture	Mparesis,7	OC Fusion	Improved
	27	M	Old	Unrep	-	Normal	L,+	None	Normal	None	3yr Normal
Cottalorda J et al, 1996, <i>J Pediatr Orthop</i> (10)	15	F	I	Unrep	+	Normal	R,+	None	Normal	7wkMinTrCo 1	4mo Normal
Lam CH and Stratford J, 1996, <i>Can J Neurol Sci</i> (22)	20	F	III	Unrep	Unrep	Normal	R,+	Contuse	Hpa,12	3moHalo	5yr imp 12
Urculo E et al, 1996, <i>J Neurosurg</i> (42)	62	M	III	Unrep	Unrep	Normal	R,+	Fracture	Del 9,10	None	6mo same

AUTHOR	AGE	SEX	TYPE	LOC	PAIN	PLAIN	CT	MR	EXAM	TX	OUTCOME
Noble ER and Smoker WRK, 1996, <i>Am J Neuroradiol</i> (31)	33	M	I	Unrep	Unrep	Unrep	?,+	None	Del 12	None	Unrep
	26	M	I	Unrep	Unrep	Unrep	?,+	None	GCS15	None	Unrep
	16	M	II	Unrep	Unrep	Unrep	?,+	None	GCS13	None	Unrep
	32	M	II	Unrep	Unrep	C2Fx	?,+	None	7,12	None	Unrep
	53	F	II	Unrep	Unrep	Unrep	?,+	None	GCS8	None	Unrep
	47	F	II	Unrep	Unrep	Unrep	?,+	None	GCS15	None	Unrep
	37	M	II	Unrep	Unrep	Unrep	?,+	None	GCS8	None	Unrep
	11	M	II	Unrep	Unrep	Unrep	?,+	None	GCS13	None	Unrep
	33	M	II	Unrep	Unrep	Unrep	?,+	None	GCS15	None	Unrep
	23	M	II	Unrep	Unrep	Unrep	?,+	None	Unrep	Unrep	Unrep
	39	M	III	Unrep	Unrep	IIOdFx	?,+	None	7	Halo	Unrep
	88	M	III	Unrep	Unrep	C1,IIOdFx	?,+	None	GCS15	Halo	Unrep
	29	M	III	Unrep	Unrep	Unrep	?,+	None	Unrep	Unrep	Unrep
14	F	III	Unrep	Unrep	Unrep	?,+	None	GCS11	Collar	Unrep	
17	F	III	Unrep	Unrep	Unrep	?,+	None	GCS7	None	Unrep	
Castling B and Hicks K, 1995, <i>Br J Oral Maxillofacial Surg</i> (9)	21	M	II	+	+	Normal	R,+	None	Del 12	None	2yr Normal
Emery E et al, 1995, <i>Eur Spine J</i> (15)	26	M	III	Unrep	+	Normal	L,+	Fracture	Hyperreflexic	Collar	4mo Normal
Paley MD and Wood GA, 1995, <i>Br J Oral Maxillofacial Surg</i> (34)	21	M	III	Unrep	+	Normal	L,+	Normal	Del 12	None	6mo imp 12
Stroobants J et al, 1994, <i>J Neurosurg</i> (40)	27	M	III	-	+	Normal	R,+	None	Normal	10wk collar	21moNormal
	12	F	III	-	+	C1Fx	L,+	None	Normal	4wk minerva	Normal
Wasserberg J and Bartlett RJV, 1994, <i>Neuroradiol</i> (45)	39	M	III	+	Unrep	Normal	L,+	None	Del 12	None	12
	24	M	III	+	+	Normal	L,+	None	Del Diplopia	Tx, Decomp	Normal
	16	M	III	+	Unrep	Normal	R,+	None	Brain injury	Tx, collar	3mo 12
	34	M	III	Unrep	Unrep	Normal	R,+	None	Unrep	Tx, halo	Unrep
Young WF et al, 1994, <i>Neurosurgery</i> (47)	26	F	III	+	Unrep	Normal	L,+	None	Hpa, 9-12	12wk halo collar	14mo imp9-12
	20	M	III	+	Unrep	Normal	R,+	None	GCS7	collar	1yr Hpa
Mann FA and Coheen W, 1994, <i>Am J Radiol</i> (27)	23	M	III	-	+	Normal	R,+	None	Normal	6wk collar	Normal
Olsson R and Kunz R, 1994, <i>Acta Radiologica</i> (32)	43	M	III	Unrep	-	Normal	L,+	None	Normal	Collar	Normal

AUTHOR	AGE	SEX	TYPE	LOC	PAIN	PLAIN	CT	MR	EXAM	TX	OUTCOME
Sharma BS et al, 1993, <i>Clin Neurol and Neurosurg</i> (37)	35	M	II	Unrep	Unrep	Normal	L,+	None	9,10	Decomp	3mo imp 9,10
Massaro F and Lanotte M, 1993, <i>Injury</i> (29)	21	M	III	Unrep	Unrep	Normal	L,+	None	Hsensory, 12	8wk minerva	2yr 12
Raila FA et al, 1993, <i>Skeletal Radiol</i> (35)	25 67	M M	III III	+ -	+ +	Normal C1abnormal	L,+ L,+	None None	Normal Normal	6wk collar collar	Normal Normal
Bettini N et al, 1993, <i>Skeletal Radiol</i> (3)	39 24 21 21	F M F M	I II III III/III	Unrep + + Unrep	+ Unrep Unrep +	C3fx Normal Unrep Normal	L,+ R,+ ?,+ B,+	None None Contuse None	Normal Coma Coma Normal	Unrep Unrep Unrep Unrep	Unrep Unrep Unrep Unrep
Leventhal MR et al, 1993, <i>Orthopaedics</i> (25)	42 19 43 17 36 17	F F M F M M	II III III II I I	+ + Unrep + + +	Unrep + + Unrep GCS8 GCS4	Normal Normal C5fx L1fx T1fx Normal	L,+ L,+ R,+ R,+ R,+ R,+	None None None None None None	6,7 Normal Normal GCS10 GCS8 GCS4	3mo collar Collar 3mo collar 3mo collar 3mo halo 3mo collar	Unrep Unknown Normal Normal Normal Normal
Mody BS and Morris EW, 1992, <i>Injury</i> (30)	21	M	III	+	Unrep	STS	L,+	None	Unrep	Tx,6wk collar	18mo no sxs
Bozboga M et al, 1992, <i>Spine</i> (7)	34 37	F M	III III	+ +	+ Unrep	Normal Unrep	L,+ L,+	None None	Lhpa,diplopia Del vertigo	Late Decomp Del 8wk collar	4yr Normal 3yr Normal
Bridgman SA and McNab W, 1992, <i>Surg Neurol</i> (8)	32	M	III	+	+	Normal	L,+	None	Del 10-12	Collar	1yr imp 10-12
Wani MA et al, 1991, <i>J Trauma</i> (44)	67	M	II	+	Unrep	+ condfx	L,None	None	9-12	None	10,12
Wessels LS, 1990, <i>S Afr J Surg</i> (46)	26 7mo 27	M M M	III II II	+ + +	+ Unrep Unrep	Unrep Unrep Unrep	R,+ L,+ R,+	None None None	7-12 5,7-12 7-12	Collar Collar Collar	6wk imp 7-12 4mo 7-12 6wk imp
Mariani PJ, 1990, <i>Ann Emerg Med</i> (28)	30	M	III	+	-	STS	R,-	None	Normal	8wk collar	Normal
Jones DN et al, 1990, <i>Am J Neuroradiol</i> (21)	43	M	III/III	+	Unrep	+ confx	B,+	Contuse	Qplegia	OCF	4wk Qplegia
Desai SS et al, 1990, <i>J Trauma</i> (14)	33	M	III	-	+	Normal	L,+	None	6	Collar	4mo Normal

AUTHOR	AGE	SEX	TYPE	LOC	PAIN	PLAIN	CT	MR	EXAM	TX	OUTCOME
Valaskatzis EP and Hammer AJ, 1990, <i>S African Med J</i> (43)	19	M	III	+	+	Normal	R,+	None	Normal	6wk collar	Normal
Orbay T et al, 1989, <i>Surg Neurol</i> (33)	37	M	III	Unrep	+	Normal	L,+ (tomo-)	None	Del 12	None	15mo 12
Savolaine ER et al, 1989, <i>J Orthop Trauma</i> (36)	71	F	III	+	+	Normal	R,+	None	Hplegia, 6	Tr, Halo	Lmparesis
Anderson PA and Montessano PX, 1988, <i>Spine</i> (1)	3 18 22 23 25 37	M F M M M M	I III III III III II	+	Unrep Unrep Unrep Unrep Unrep Unrep	Normal Normal Normal Normal Normal Normal	R,+ ?,+ R,Tomo+ L,+ ?,Tomo+ L,+	None None None None None None	Uncon Unrep Uncon Uncon Unrep Uncon	Soft Minerva Halo Collar Minerva Collar	24mo normal 36 mo 12mo normal death 17mo 12mo normal
Curri D et al, 1988, <i>J Neurosurg Sci</i> (11)	16	F	III	+	Unrep	Normal	R,+	None	Decerebrate	Collar	6mo Unrep
Hashimoto T et al, 1988, <i>Neurosurgery</i> (18)	71	M	II	-	Unrep	Normal	L,+	None	9-12	None	6mo 9-12
Deeb ZI et al, 1988, <i>J Computed Tomography</i> (12)	25 66	F F	II Old	Unrep Unrep	Unrep +	Normal None	DelL,+ DelL,+	None Fracture	12 Normal	None None	Unrep Unrep
Spencer JA et al, 1984, <i>Neurosurgery</i> (38)	19	M	I	+	GCS8	Normal	L,+	None	GCS8	ColHalo	B910
Goldstein SJ et al, 1982, <i>Surg Neurol</i> (16)	24	F	III	Unrep	+	C56slx	L,Tomo+	None	Normal	2mocoll	NI
Harding-Smith J et al, 1981, <i>J Bone Joint Surg</i> (17)	18	M	III	+	Unrep	STS	R,Tomo+	None	Uncon	Collar	16moNI
Bolender N et al, 1978, <i>Am J Radiol</i> (6)	23 22	M M	III II	Unrep Unrep	Unrep Unrep	Normal Normal	R,Tomo+ R,Tomo+	None None	9-12 Del 6,9,10	None None	Unrep Unrep

REFERENCES

1. Anderson PA, Montesano PX. Morphology and treatment of occipital condyle fractures. *Spine* 13:731-736, 1988.
2. Bell C. Surgical observations. *Middlesex Hosp J* 4:469, 1817.
3. Bettini N, Malaguti MC, Sintini M, Monti C. Fractures of the occipital condyles: report of four cases and review of the literature. *Skeletal Radiol* 2:187-190, 1993.
4. Bloom AI, Neeman Z, Slasky BS, Floan Y, Milgrom M, Rivkind A, Bar-Ziv J. Fracture of the occipital condyles and associated craniocervical ligament injury: incidence, CT imaging and implications. *Clin Radiol* 52:198-202, 1997.
5. Bloom AI, Neeman Z, Floman Y, Gomori J, Bar-Ziv J. Occipital condyle fracture and ligament injury: imaging by CT. *Pediatr Radiol* 26:786-790, 1996.
6. Bolender N, Cromwell LD, Wendling L. Fracture of the occipital condyle. *Am J Radiol* 131:729-731, 1978.
7. Bozboga M, Unal F, Hepgul K, Izgi N, Turantan I, Tucker K. Fracture of the occipital condyle. Case report. *Spine* 17:1119-1121, 1992.
8. Bridgman SA, McNab W. Traumatic occipital condyle fracture, multiple cranial nerve palsies, and torticollis: a case report and review of the literature. *Surg Neurol* 38:152-156, 1992.
9. Castling B, Hicks K. Traumatic isolated unilateral hypoglossal nerve palsy-case report and review of the literature. *Br J Oral Maxillofacial Surg* 33:171-173, 1995.
10. Cottalorda J, Allard D, Dutour N. Case report: Fracture of the occipital condyle. *J Pediatr Orthop* 5:161-163, 1996.

11. Curri D, Cervellin P, Zanusso M, Benedetti A. Isolated fracture of the occipital condyle. Case report. *J Neurosurg Sci* 32:157-159, 1988.
12. Deeb ZL, Rothfus WE, Goldberg AL, Dafner RH. Occult occipital condyle fractures presenting as tumors. *J Computed Tomography* 12:261-263, 1988.
13. Demisch S, Linder A, Beck R, Zierz S. Case report. The forgotten condyle: delayed hypoglossal nerve palsy caused by fracture of the occipital condyle. *Clin Neurol Neurosurg* 100:44-45, 1998.
14. Desai SS, Coumas JM, Danylevich A, Hayes E, Dunn EJ. Fracture of the occipital condyle: case report and review of the literature. *J Trauma* 30:240-241, 1990.
15. Emery E, Saillant G, Ismail M, Fohamo D, Roy-Camille R. Fracture of the occipital condyle: case report and review of the literature. *Eur Spine J* 4:191-193, 1995.
16. Goldstein SJ, Woodring JH, Young AB. Occipital condyle fracture associated with cervical spine injury. *Surg Neurol* 17:350-352, 1982.
17. Harding-Smith J, MacIntosh PK, Sherbon KJ. Fracture of the occipital condyle. A case report and review of the literature. *J Bone Joint Surg* 63A:1170-1171, 1981.
18. Hashimoto T, Watanabe O, Takase M, Koniya J, Kobota M. Collet-Sicard syndrome after minor head trauma. *Neurosurg* 23:367-370, 1998.
19. Ide C, Nisolle JF, Misson N, Trigaux JP, Gustin T, DeCoene B, Gilliard C. Unusual occipitoatlantal fracture dissociation with no neurological impairment. Case report. *J Neurosurg* 88:773-776, 1998.
20. Jacoby CG. Fracture of the occipital condyle. *Am J Radiol* 132:500, 1979.

21. Jones DN, Knox AM, Sage MR. Traumatic avulsion fracture of the occipital condyles and clivus with associated unilateral atlantooccipital distraction. *Am J Neuroradiol* 11:1181-1183, 1990.
22. Lam CH, Stratford J. Bilateral hypoglossal nerve injury with occipital condylar fracture. *Can J Neurol Sci* 23:145-148, 1996.
23. Legros B, Fournier P, Chiaroni P, Ritz O, Fusciardi J. Basal fracture of the skull and lower (IX, X, XI, XII) cranial nerves palsy: four case reports including two fractures of the occipital condyle- a literature review. *J Trauma, Injury, Infection Crit Care* 48:342-348, 2000.
24. Leone A, Cerase A, Colosimo C, Lauro L, Puca A, Marano P. Occipital condylar fractures: a review. *Radiol* 216:635-644, 2000.
25. Leventhal MR, Boydston WR, Sebes JI, Pinstein ML, Watridge CB, Lowrey R. The diagnosis and treatment of fractures of the occipital condyle. *Orthopaedics* 15:944-947, 1992.
26. Link TM, Schuierer G, Hufendiek A, Horch C, Peters PE. Substantial head trauma: Value of routine CT examination of the cervicocranium. *Radiology* 196:741-745, 1995.
27. Mann FA, Coheen W. Occipital condyle fracture: significance in the assessment of occipitoatlantal stability. *Am J Radiol* 163:193-194, 1994.
28. Mariani PJ. Occipital condyle fracture presenting as a retropharyngeal hematoma. *Ann Emerg Med* 19:1447-1449, 1990.
29. Massaro F, Lanotte M. Case reports. Fracture of the occipital condyle. *Injury* 24:419-420, 1993.

30. Mody BS, Morris EW. Fracture of the occipital condyle: Case report and review of the world literature. *Injury* 23:350-352, 1992.
31. Noble ER, Smoker WRK. The forgotten condyle: the appearance, morphology, and classification of occipital condyle fractures. *Am J Neuroradiol* 17:507-513, 1996.
32. Olsson R, Kunz R. Fracture of the occipital condyle as an incidental finding during CT-evaluation of a maxillary fracture. *Acta Radiologica* 7:90-91, 1994.
33. Orbay T, Aykol S, Seckin Z, Ergun R. Late hypoglossal nerve palsy following fracture of the occipital condyle. *Surg Neurol* 31:402-404, 1989.
34. Paley MD, Wood GA. Traumatic bilateral hypoglossal nerve palsy. *Br J Oral Maxillofacial Surg* 33:239-241, 1995.
35. Raila FA, Aitken AT, Vivkers GN. Computed tomography and three-dimensional reconstruction in the evaluation of occipital condyle fracture. *Skeletal Radiol* 22:269-271, 1993.
36. Savolaine ER, Ebraheim NA, Jackson WT, Rusin JJ. Case report. Three-dimensional computed tomography in evaluation of occipital condyle fracture. *J Orthop Trauma* 3:71-75, 1989.
37. Sharma BS, Mahajan S, Khosla VK. Case report. Collet-Sicard syndrome after closed head injury. *Clin Neurol and Neurosurg* 96:197-198, 1994.
38. Spencer JA, Yeakley JW, Kaufman HH. Fracture of the occipital condyle. *Neurosurgery* 15:101-103, 1984.

39. Stroobants J, Fidlers L, Storms JL, Klaes R, Dua G, Van Hoyer M. High cervical pain and impairment of skull mobility as the only symptoms of an occipital condyle fracture. *J Neurosurg* 81:137-138, 1994.
40. Stroobants J, Seynaeve P, Fidlers L, Klaes R, Brabants K, Van Hoyer M. Occipital condyle fracture must be considered in the pediatric population: case report. *J trauma* 36:440-441, 1994.
41. Tuli S, Tator CH, Fehlings MG, Mackay M. Occipital condyle fractures. *Neurosurgery* 41:368-377, 1997.
42. Urculo E, Arrazola M, Arrazola M, Riu I, Moyua A. Delayed glossopharyngeal and vagus nerve paralysis following occipital condyle fracture. Case report. *J Neurosurg* 84:522-525, 1996.
43. Valaskatzis EP, Hammer AJ. Fracture of the occipital condyle. A case report. *S African Med J* 77:47-48, 1990.
44. Wani MA, Tandon PN, Banerji AK, Bhatia R. Collet-Sicard syndrome resulting from closed head injury: case report. *J Trauma* 31:1437-1439, 1991.
45. Wasserberg J, Bartlett RJV. Occipital condyle fractures diagnosed by high-definition CT and coronal reconstructions. *Neuroradiol* 37:370-373, 1995.
46. Wessels LS. Fracture of the occipital condyle: A report of three cases. *S Afr J Surg* 28:155-156, 1990.
47. Young WF, Rosenwasser RH, Getch C, Jallo J. Diagnosis and management of occipital condyle fractures. *Neurosurgery* 34:257-261, 1994.

FIGURE 1 Classification of occipital condyle fractures according to Anderson and Montesano. Type I fractures (A) may occur with axial loading. Type II fractures (B) are extensions of a basilar skull fracture. Type III fractures (C) may result from an avulsion of the condyle during rotation, lateral bending, or a combination of mechanisms.

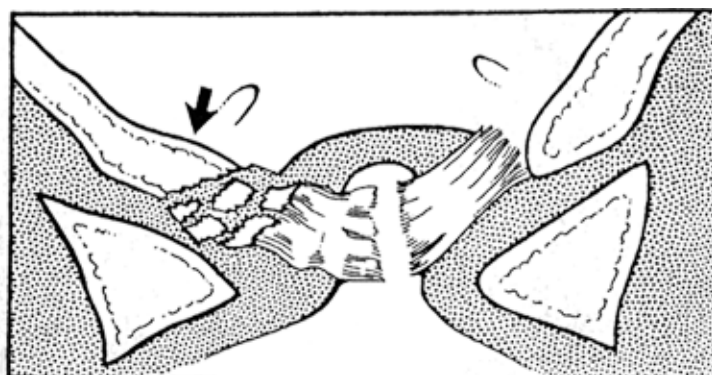


Figure 1A

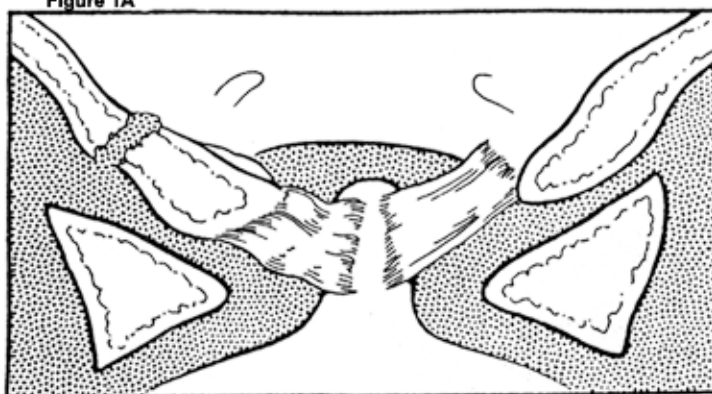


Figure 1B

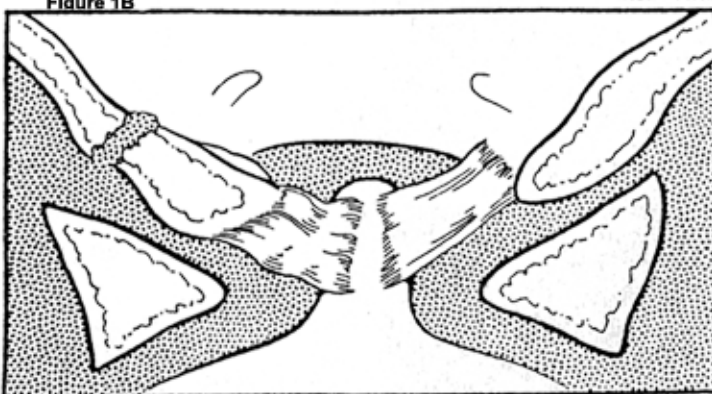


Figure 1C